

SAN ROQUE

DIAGNOSTIC CENTER

DINGLASAN ST. MARSAN VILLAGE, SAN ROQUE, SJOM
MOBILE NO.: 0931-115- 1848



ULTRASOUND REPORT

NAME: CASTICIMO, LUCELLE
ADDRESS: LABANGAN, SAN JOSE OCC. MDO.
REQUESTING PHYSICIAN: DR. PAULINO

DATE: 05-27-2023

AGE: 35 SEX: F

LMP: 01-14-23
Fetal number: Single
Fetal presentation: Cephalic
Placental Localization: Anterior, Grade I
Fetal heart rate: 147/bpm
Fetal movement: Active
Amniotic fluid: Adequate
Sex: Boy

CLINICAL DATA:

LMP weeks:	19.0 wks.		
CRL:			
CRL weeks:			
HC:	16.81 cm	FL:	3.09 cm
HC weeks:	19 weeks and 3 days	FL weeks:	19 weeks and 4 days
BPD:	4.55 cm	AC:	13.55 cm
BPD weeks:	19 weeks and 5 days	AC weeks:	19 weeks and 0 day
Average Gestation:	19 weeks and 3 days	EFW:	285 grams
EDC:	October 18, 2023		

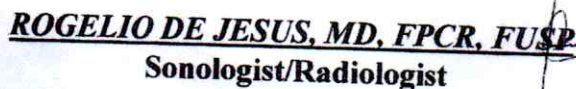
IMPRESSION:

- SINGLE, LIVE, INTRAUTERINE PREGNANCY, IN CEPHALIC PRESENTATION OF ABOUT 19 WEEKS AND 3 DAYS AGE OF GESTATION BASED ON FETAL BIOMETRY
- ULTRASOUND EDC: OCTOBER 18, 2023


Marcel F. Paragon, RRT

Lic. No. 0008201

Radiologic Technologist


ROGELIO DE JESUS, MD, FPCR, FUSP
Sonologist/Radiologist

Please correlate with clinical and/ or laboratory findings. THANK YOU for the referral!